



# Indian Society of Paediatric Radiology

(Founded in 2003)  
[www.ispronline.in](http://www.ispronline.in)

## **ISPR Office Bearers**

### **National President**

Dr. Bijon Kundu

### **Immediate PP**

Dr. Akshay K Saxena

### **President Elect**

Dr. Kushaljit S Sodhi

### **Vice Presidents**

Dr. Priscilla Joshi

Dr. Jeetendra Sharma

### **Secretary General**

Dr. Sridhar Gibikote

### **Joint Secretaries**

Dr. Kushal B Gehlot

Dr. Anit Parihar

### **Treasurer**

Dr. Anmol Bhatia

### **Executive Committee**

Dr. N. Chidambaranathan

Dr. K. Gopinathan

Dr. Manisha Jana

Dr. C.V. Kanimozhi

Dr. Taruna Yadav

Dr. Hiren Panwala

Dr. Ishan Kumar

## **ISPR NEWSLETTER**

**DECEMBER  
2025**

**Year: 16**

**Issue: 2**

**Continuous issue no. : 27**

**WEBSITE: [www.ispronline.in](http://www.ispronline.in)**



2026

Happy  
New Year

*Dr. Bijon Kundu*  
President ISPR

*Dr. Sridhar Gibikote*  
Secretary ISPR



# Indian Society of Paediatric Radiology

Year: 16 Issue: 2  
Continuous issue no. : 27

(Founded in 2003)  
[www.ispronline.in](http://www.ispronline.in)

## **ISPR Office Bearers**

### **National President**

Dr. Bijon Kundu

### **Immediate PP**

Dr. Akshay K Saxena

### **President Elect**

Dr. Kushaljit S Sodhi

### **Vice Presidents**

Dr. Priscilla Joshi

Dr. Jeetendra Sharma

### **Secretary General**

Dr. Sridhar Gibikote

### **Joint Secretaries**

Dr. Kushal B Gehlot

Dr. Anit Parihar

### **Treasurer**

Dr. Anmol Bhatia

### **Executive Committee**

Dr. N. Chidambaranathan

Dr. K. Gopinathan

Dr. Manisha Jana

Dr. C.V. Kanimozhi

Dr. Taruna Yadav

Dr. Hiren Panwala

Dr. Ishan Kumar

## Table of contents

4. Note from the Editor
5. Upcoming Events
9. Interesting case
11. Quiz
12. ISPR Annual Conference 2025
17. Presentations and Invited Lectures
22. Publications by our members
24. Achievements & Awards
28. Quiz answer
29. Social Media activities
30. Useful resources
31. Membership Registration form



# Indian Society of Paediatric Radiology

Year: 16 Issue: 2  
Continuous issue no. : 27

(Founded in 2003)  
[www.ispronline.in](http://www.ispronline.in)

## Editor's Desk

Season's Greetings to all ISPR members!

We are pleased to present this end-of-year edition of the Newsletter which features some exciting new additions and changes.

In keeping with ISPR's commitment to be more inclusive and to actively involve junior members, we are delighted to welcome Dr. Nikshita Jain as Co-Editor of ISPR Newsletter. We eagerly look forward to her fresh new ideas to elevate the quality of the Newsletter.

This year, ISPR has significantly enhanced its social media presence thanks to the efforts and contributions of our various new subcommittees. We encourage all members to regularly visit the ISPR website and engage with our social media channels.

The ISPR Annual Conference at Lucknow in September 2025 was a resounding success, featuring insightful lectures from both national and international experts. Congratulations Team Indore !

May ISPR grow in strength, inspire and educate for many years to come !

Warm regards,  
**Dr. C.V.Kanimozhi**  
Editor ISPR Newsletter



Wishing all our members a very happy and successful New Year. This issue marks my first contribution as Co-Editor of the ISPR Newsletter. Since my foray into pediatric radiology, I have had the privilege of attending the Annual, Midterm, and Outreach programmes conducted by ISPR, and it is deeply gratifying to now contribute to this initiative. I sincerely thank the ISPR Executive Committee for this opportunity and am grateful to be part of this vibrant academic community. I look forward to continuing this engagement and contributing to our shared academic growth in the years ahead.

Warm Regards,  
**Dr. Nikshita Jain**  
Co-editor ISPR Newsletter



# Indian Society of Paediatric Radiology

Year: 16 Issue: 2  
Continuous issue no. : 27



(Founded in 2003)  
[www.ispronline.in](http://www.ispronline.in)


## Upcoming Events

**IPR CO-PRESIDENTS**

**MICHAEL J. CALLAHAN, MD**  
SOCIETY FOR PEDIATRIC RADIOLOGY

**PROF. RICK R. VAN RIJN, MD, PHD**  
EUROPEAN SOCIETY OF PAEDIATRIC RADIOLOGY



WORKING TOWARDS SUSTAINABLE  
PEDIATRIC RADIOLOGY




THE WORLD IS FACING CHALLENGES WITH  
REGARDS TO THE ENVIRONMENT AND THE  
WELLBEING OF PEOPLE.

WHAT IS OUR ROLE AS PEDIATRIC RADIOLOGISTS

JOIN US TO DISCUSS THESE ISSUES, TACKLE THE  
PROBLEMS, AND FIND SOLUTIONS

**2026 INTERNATIONAL PEDIATRIC RADIOLOGY (IPR) CONGRESS**

**JUNE 1 - 5 | HILTON BOSTON PARK PLAZA | BOSTON, MA**

THE IPR IS THE PERFECT OPPORTUNITY TO  
EXCHANGE KNOWLEDGE AND FOSTER OLD &  
NEW FRIENDSHIPS. DON'T MISS OUT ON THIS  
UNIQUE OPPORTUNITY TO LEARN AND

<https://www.spr.org/events/ipr2026>



February 5, 2026 at 11:00 AM (EST) to February 6, 2026 at 6:00 PM (EST)

**SPR & ST. JUDE CHILDREN'S RESEARCH HOSPITAL**

PRESENT

**PEDIATRIC ONCOLOGIC IMAGING COURSE**

In-Person at St. Jude and Live Online

<https://www.spr.org/events/oncologicimaging2026>



# Indian Society of Paediatric Radiology

Year: 16 Issue: 2  
Continuous issue no. : 27

(Founded in 2003)  
[www.ispronline.in](http://www.ispronline.in)

## Upcoming Events



EUROPEAN SOCIETY  
OF NEURORADIOLOGY  
Diagnostic and Interventional



ESPR  
European Society of Paediatric Radiology

### European Course on Pediatric Neuroradiology

3<sup>rd</sup> Cycle Module 1

Jointly organized by ESNR & ESPR

31 January - 4 February 2026  
Athens - Greece

ECPNR 2026 13-1

<https://www.esnr.org>



EUROPEAN SOCIETY OF NEURORADIOLOGY  
DIAGNOSTIC AND INTERVENTIONAL

## 2<sup>nd</sup> European Pediatric Neuroradiology Congress

<https://www.espr.org/event>

EPNC 2026 GENOVA 28-31 October 2026 - Genoa, Italy



# Indian Society of Paediatric Radiology

Year: 16 Issue: 2  
Continuous issue no. : 27

(Founded in 2003)  
[www.ispronline.in](http://www.ispronline.in)

## Upcoming Events



INDIAN SOCIETY OF  
PAEDIATRIC RADIOLOGY

### ISPR NATIONAL MID-TERM CME - 2026

Hosted by  
UDAIPUR CHAPTER OF RADIOLOGY

**Sunday, 15th March 2026**

at

Howard Johnson by Wyndham, Udaipur (Raj.)



**Dr Anand Gupta**  
Patron

**Dr Kushal Gehlot**  
Organizing Chairman  
9413107135

**Dr Kapil Vyas**  
Organizing Secretary  
9829065469  
Email : [dr.vyas.kapil@gmail.com](mailto:dr.vyas.kapil@gmail.com)





# Indian Society of Paediatric Radiology

Year: 16 Issue: 2  
Continuous issue no. : 27

(Founded in 2003)  
[www.ispronline.in](http://www.ispronline.in)

## Upcoming Events



**ISPR 2026**

INDIAN SOCIETY OF  
PAEDIATRIC RADIOLOGY

FOUNDED DEC. 2003  
Pondicherry

**24<sup>TH</sup> ANNUAL NATIONAL CONFERENCE**

**INDIAN SOCIETY OF  
PAEDIATRIC RADIOLOGY**

**19-20 September 2026**

**THE STADEL Kolkata**

ISPR MEMBERS		NON ISPR MEMBERS
Rs. 8850	<b>Early Bird Registration</b> <i>Open Till 15<sup>th</sup> March 2026</i>	Rs. 9440
<b>PG STUDENTS</b> Rs. 7670		<b>All Rates</b> Inclusive of GST





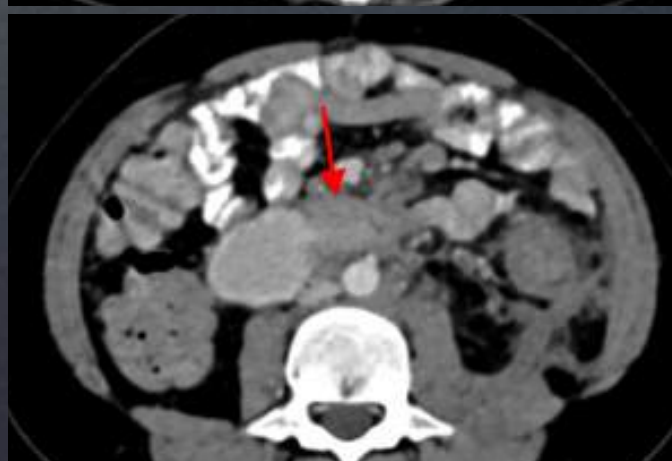
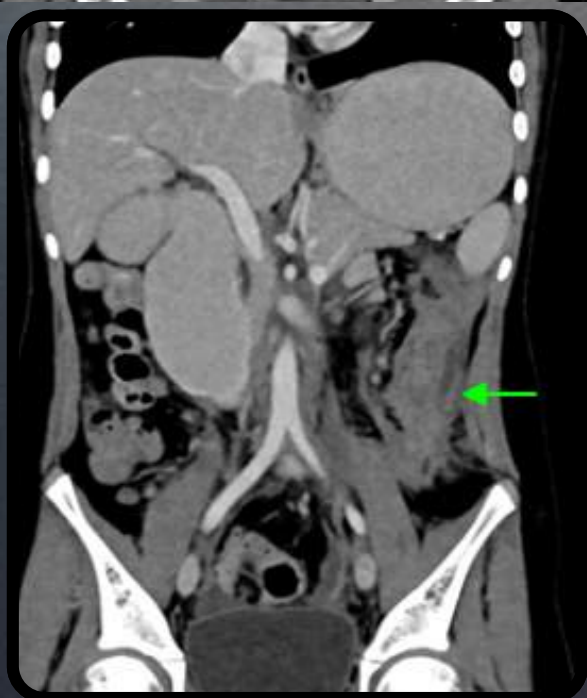
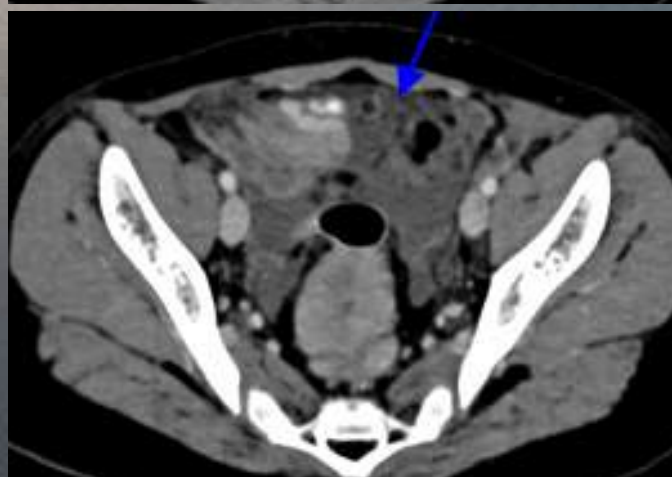
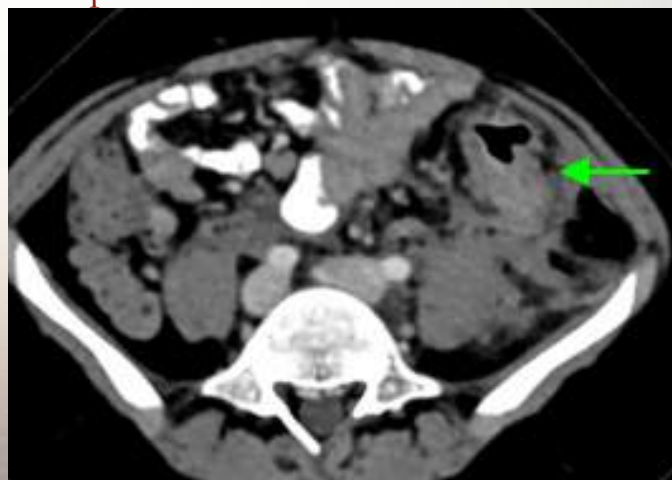
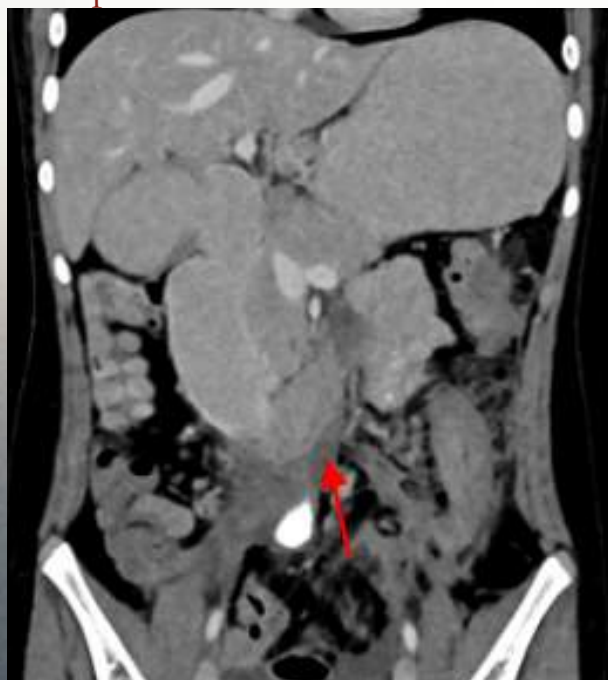# Indian Society of Paediatric Radiology

Year: 16 Issue: 2  
Continuous issue no. : 27

(Founded in 2003)  
[www.ispronline.in](http://www.ispronline.in)

## GUT FEELINGS GONE WRONG: INTERESTING CASE

A 11 year old boy came with intermittent pain in abdomen & chronic constipation since 2 years. USG revealed omental inflammation in left iliac fossa. Serum CRP was elevated, faecal calprotectin was within normal limits. CECT depicted below.



### Case contributed by:

Dr. Srividya Venkateswaran (Junior Resident, Tata Memorial Hospital, Mumbai)

Dr. Harshita Naik (Junior Resident, Tata Memorial Hospital, Mumbai)

Dr. Nikshita Jain (Consultant, BJ Wadia Children's Hospital, Mumbai)

# Indian Society of Paediatric Radiology

Year: 16 Issue: 2  
Continuous issue no. : 27

(Founded in 2003)  
[www.ispronline.in](http://www.ispronline.in)



## Interesting Case : DISCUSSION

### CECT Abdomen shows:

Segmental enhancing circumferential wall thickening of the duodenum (third and fourth part) [red arrows] with circumferential thickening of the descending colon [green arrows]; significant adjacent mesenteric and omental fat stranding [blue arrows] with reactive mesenteric nodes; and mild ascites.

### IMAGING DIFFERENTIALS:

- *Inflammatory Bowel Disease (IBD)*: long-segment bowel involvement with skip lesions. However, the presence of mural stratification, target sign, and engorged mesenteric vessels ("comb sign") are more specific for active disease. Chronic disease can present with fistulae, abscesses, and strictures.
- *Tuberculosis (TB)*: presents as short-segment bowel involvement, usually in the cecum and terminal ileum, with homogenous wall thickening. Skip involvement is uncommon, while the presence of necrotic lymphadenopathy favors its diagnosis.

### **FINAL DIAGNOSIS** (On colonoscopic biopsy):

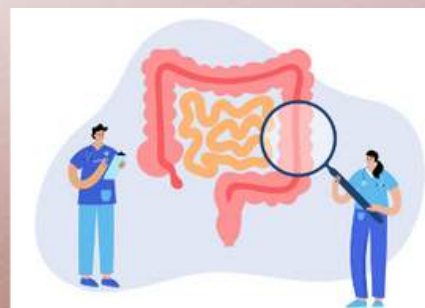Mucinous adenocarcinoma of the colon with a skip lesion in the duodenum.

### A RARE ENTITY DECODED:

- Mucinous adenocarcinoma (MAC) is a distinct histologic subtype of colorectal cancer characterized by abundant extracellular mucin, produced by tumor cells and pools within and around malignant glands.  
Mucin comprises >50% of the tumor volume.
- Colorectal carcinoma in children is a rare occurrence and has an annual incidence of roughly between 1-2 cases per million in those under 15 years.
- The prognosis of MAC can be poorer compared with conventional adenocarcinoma, possibly due to advanced stage at diagnosis, distinct tumor biology, and its poor response to chemotherapy.
- Diagnosis relies on histopathology demonstrating abundant extracellular mucin with malignant glandular cells.

#### References:

- Sharma R, Madhusudhan KS, Ahuja V. Intestinal tuberculosis versus Crohn's disease: Clinical and radiological recommendations. *Indian J Radiol Imaging*. 2016;26(2):161-72.
- M.S. Bhatia, S. Chandna, R. Shah, D.D. Patel. Colorectal Carcinoma in Indian Children. *Indian Pediatrics* 2000;37: 1353-1358.





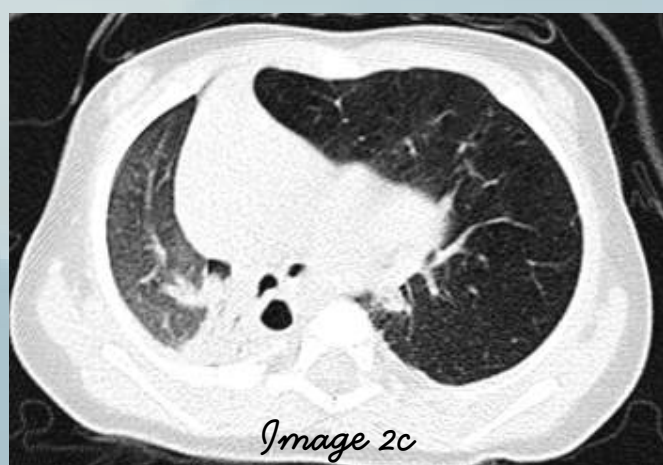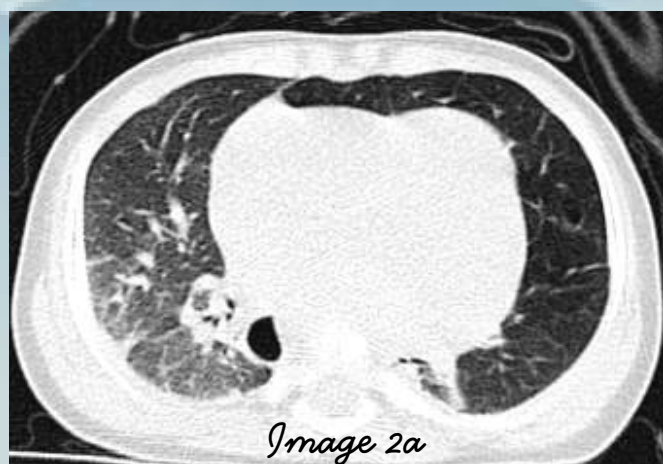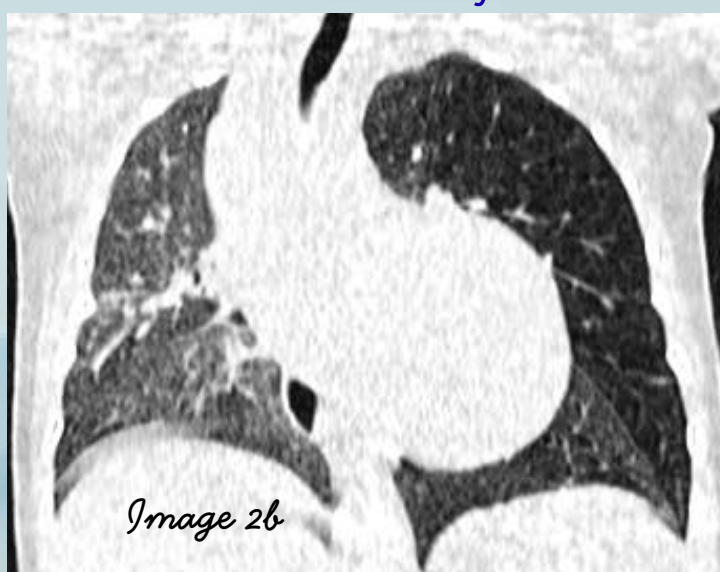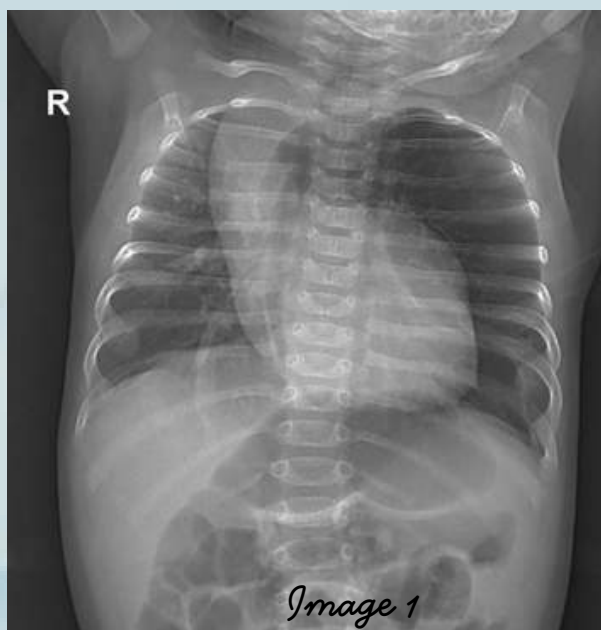# Indian Society of Paediatric Radiology

Year: 16 Issue: 2  
Continuous issue no. : 27

(Founded in 2003)  
[www.ispronline.in](http://www.ispronline.in)

## QUIZ TIME

Infant with breathlessness since birth.  
No evidence of cyanosis



Case contributed by:  
Dr. Sneha Zanje (Jupiter Hospital, Thane)  
Dr. Priya Chudgar (Jupiter Hospital, Thane)

**Quiz answer on page 28**

# Indian Society of Paediatric Radiology

Year: 16 Issue: 2  
Continuous issue no. : 27

(Founded in 2003)  
[www.ispronline.in](http://www.ispronline.in)

## 23<sup>rd</sup> Annual Conference ISPR 2025 Indore

The 23<sup>rd</sup> Annual Conference of the Indian Society of Paediatric Radiology (ISPR) 2025 was successfully held at the Brilliant Convention Center in Indore from 20 - 21 September. This conference achieved remarkable success and set new benchmarks in academic excellence.

The Organising Chairperson, Dr. Rajendra K. Sodani and Organising Secretary Dr. Abhijeet Taori, along with their dedicated Core Organising Team, ensured enthusiastic participation from delegates, speakers, volunteers and sponsors alike. Over 325 delegates and faculty members from around the world attended, representing academia, industry, and research institutions, which reflects the expanding global influence of ISPR. More than 50 expert lectures were delivered by eminent speakers covering a wide spectrum of topics in paediatric radiology. The conference enjoyed full attendance till the closing session, which is a testament to the high calibre of academic content.

Dr. K. Devasenathipathy delivered the Prof. M.V.K. Shetty Endowment Oration, speaking on 'Imaging in Pediatric Abdominal Masses'. Dr. Aparna Irodi delivered the Prof. Arcot Gajaraj Endowment Oration, speaking on 'Update in bronchopulmonary malformations'.

The success of ISPR 2025 underscores the Society's commitment to advancing excellence in paediatric radiology..



# Indian Society of Paediatric Radiology

Year: 16 Issue: 2  
Continuous issue no. : 27

(Founded in 2003)  
[www.ispronline.in](http://www.ispronline.in)

## ISPR 2025 Indore



Lamp lighting  
by the  
dignitaries



# Indian Society of Paediatric Radiology

Year: 16 Issue: 2  
Continuous issue no. : 27

(Founded in 2003)  
[www.ispronline.in](http://www.ispronline.in)

## ISPR 2025 Indore



**Dr. Bijon Kundu  
delivering the  
Presidential Address**

**Dr. Sridhar Gibikote  
delivering the  
Secretary's Report**





# Indian Society of Paediatric Radiology

Year: 16 Issue: 2  
Continuous issue no. : 27

(Founded in 2003)  
[www.ispronline.in](http://www.ispronline.in)

## ISPR 2025 Orations

**Dr.K.Devasenathipathy**  
**Prof. MVK Shetty Oration**



**Dr. Aparna Irodi**  
**Prof. Arcot Gajaraj Oration**





# Indian Society of Paediatric Radiology

Year: 16 Issue: 2  
Continuous issue no.: 27

(Founded in 2003)  
[www.ispronline.in](http://www.ispronline.in)

## ISPR 2025 Indore





# Indian Society of Paediatric Radiology

Year: 16 Issue: 2  
Continuous issue no. : 27

(Founded in 2003)  
[www.ispronline.in](http://www.ispronline.in)

## Presentations & Invited lectures

**Dr. Kushaljit S. Sodhi**, President Elect ISPR, was invited as faculty speaker and delivered a lecture titled 'Variants and Pitfalls in Pediatric MSK Imaging' at the **25th Annual Scientific Meeting of the Asian and Oceanic Society for Paediatric Radiology (AOSPR)** held at Doha, Qatar from October 24 - 26, 2025.



# Indian Society of Paediatric Radiology

Year: 16 Issue: 2  
Continuous issue no. : 27

(Founded in 2003)  
[www.ispronline.in](http://www.ispronline.in)

## Invited lectures



## AOSPR 2025, Doha





# Indian Society of Paediatric Radiology

Year: 16 Issue: 2  
Continuous issue no. : 27

(Founded in 2003)  
[www.ispronline.in](http://www.ispronline.in)

## Presentations & Invited lectures

**Dr. Priscilla Joshi**, Prof. and Head, Dept. of Radiodiagnosis, Bharati Vidyapeeth Deemed University, Pune and **Dr. Nikshita Jain**, Consultant Pediatric Radiologist, BJ Wadia Children's Hospital, Mumbai, were invited as faculty speakers at the 'CME on Pediatric Radiology'. This event was organised by the Radiological & Imaging Association Nagpur branch, Vidarbha Chapter of MSBIRIA 2025-26, on 15th June 2025 in Nagpur, Maharashtra.



# Indian Society of Paediatric Radiology

Year: 16 Issue: 2  
Continuous issue no. : 27

(Founded in 2003)  
[www.ispronline.in](http://www.ispronline.in)

## Presentations & Invited lectures

**Dr. Hiren Panwala**, Consultant Pediatric Radiologist & Clinical Lead, NH SRCC Children's Hospital, Mumbai, was invited as faculty speaker at the below meetings.

1. Participated as faculty in 'Workshop in Pediatric Epilepsy' at the National Pediatric Epilepsy Conference [NPEC] 2025, Nagpur, Maharashtra.
2. Participated as faculty in 'Pre-conference workshop on respiratory imaging' at the Maha Respiratory Conclave, Pediatric Pulmonology Society, Sangli, August 2025.
3. Delivered lecture on 'Pediatric cardiac CT minimal radiation, maximum output' at the Pediatric Cardiac Society of India [PCSI] Annual conference, Mumbai, September 2025.
4. Participated as faculty in 'Comprehensive Pediatric respiratory workshop on imaging' at the MAHAPEDICON, Kolhapur, October 2025.
5. Presented E- poster on 'Mixed total anomalous pulmonary venous connection (TAPVC): The indispensable role of imaging in guiding surgical decisions and improving post-operative outcome'. C-26998 at ECR 2025.





# Indian Society of Paediatric Radiology

Year: 16 Issue: 2  
Continuous issue no. : 27

(Founded in 2003)  
[www.ispronline.in](http://www.ispronline.in)

## Presentations & Invited lectures

**Dr. Kannan Gunasekaran**, Lead Consultant, Pediatric Radiology, Kovai Medical Centre & Hospital, Tamilnadu, presented a paper titled 'Innovative image guided dual site epidural drainage in a neonate with extensive spinal abscess and sepsis' at the 13<sup>th</sup> International meeting of the Society for Pediatric Interventional Radiology (SPIR), Sydney, Australia, October 14 -16, 2025.



**Dr. Akhila Dwaraknath**, Chief Consultant Radiologist, Sarji Group of Hospitals, Shimoga was invited as faculty speaker and delivered a lecture on 'Ultrasound in Pediatric Acute Abdomen' at SonoSummit 2025, Chennai, June 27 -29, 2025.



# Indian Society of Paediatric Radiology

Year: 16 Issue: 2  
Continuous issue no. : 27

(Founded in 2003)  
[www.ispronline.in](http://www.ispronline.in)

## Publications by ISPR members

**Dr. Kushaljit S. Sodhi**, President Elect ISPR , has published the following original research articles.

1. Hull NC, Shabani A, Daltro P, **Sodhi KS**, Maxfield C, Lee EY. How I Do It: Imaging Evaluation of Neonatal Bowel Obstructions. Radiology. 2025 Jun;315(3):e241778. doi: 10.1148/radiol.241778. PMID: 40459415.
2. Laya BF, Concepcion NDP, Yap JLD, Kritsaneepaiboon S, **Sodhi KS**, Lee EY. Advances in Pediatric Large Airway Imaging: Looking Back and Looking Forward. Radiol Clin North Am. 2025 Sep;63(5):731-755. doi: 10.1016/j.rcl.2025.03.007. Epub 2025 Jun 10. PMID: 40713439.



# Indian Society of Paediatric Radiology

Year: 16 Issue: 2  
Continuous issue no. : 27

(Founded in 2003)  
[www.ispronline.in](http://www.ispronline.in)

## Publications by ISPR members

**Dr. Ishan Kumar**, Professor, Dept. of Radiodiagnosis and Imaging, Banaras Hindu University, Varanasi, has published the following original research articles.

1.. Yadav V, **Kumar I**, Chaudhary AK, Yadav N, Aggarwal P, Meena LP, Verma A. From Childhood to Adulthood: Investigating the Utility of Radiographic Pettersson Score in Assessing Hemophilic Arthropathy Severity. Indian Journal of Radiology and Imaging. 2025. Epub ahead of print.

2. **Kumar I**, Verma A, Aggarwal P, Yadav N, Kukreja K, Singh PK. Radiological insights into pediatric undernutrition: Early detection, complications, and a structured evaluation approach. Curr Probl Diagn Radiol. 2025;54(5):616-626



**Dr. K. Gopinathan**, Head, Dept. of Radiology, Govt. Kilpauk Medical College, Chennai & **Dr. Nikshita Jain**, Consultant Pediatric Radiologist, BJ Wadia Children's Hospital, Mumbai, have published the following original research article.

**K Gopinathan, Jain N**, Jyotsna. Neuroimaging in inborn errors of metabolism: diagnostic patterns and clinical implications. Indian J Pract Pediatr. 2025 Jul-Sep;27(3):258-274.

# Indian Society of Paediatric Radiology

Year: 16 Issue: 2  
Continuous issue no. : 27

(Founded in 2003)  
[www.ispronline.in](http://www.ispronline.in)

## Achievements & Awards

It has been formally announced that **Dr. Akshay Kumar Saxena**, Past President ISPR, will receive the Honorary Membership Award from the Society of Pediatric Radiology (**SPR**) during the International Pediatric Radiology Congress (IPR) in June 2026. We extend our congratulations on this outstanding achievement, which serves as a significant source of pride for the ISPR community.

*Congratulations*



# Indian Society of Paediatric Radiology

Year: 16 Issue: 2  
Continuous issue no. : 27

(Founded in 2003)  
[www.ispronline.in](http://www.ispronline.in)

## Achievements & Awards

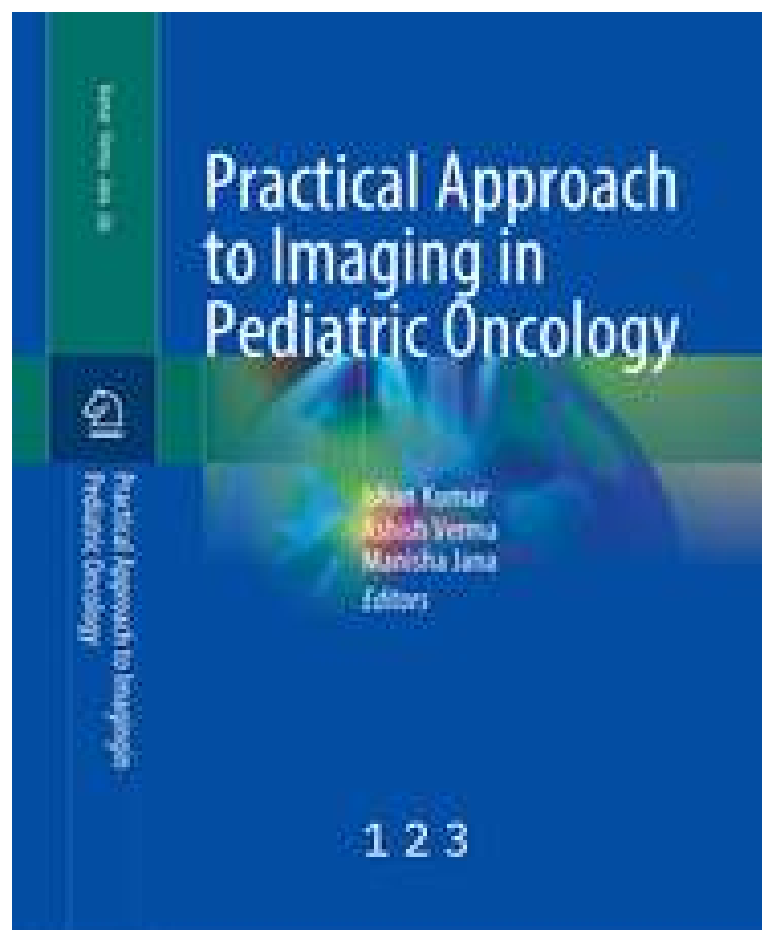
We are pleased to announce that Dr. Ishan Kumar, Professor, Dept. of Radiodiagnosis and Imaging, Banaras Hindu University, Varanasi, has published a book titled '**Practical Approach to Imaging in Pediatric Oncology**' through Springer publications.

- **Editors: Ishan Kumar, Ashish Verma, Manisha Jana**

The following ISPR members have authored and contributed to the chapters in this book:

- Dr. Priscilla Joshi
- Dr. Sridhar Gibikote
- Dr. Kushaljit S. Sodhi
- Dr. Shyamkumar N. Keshava
- Dr. Poonam Sherwani
- Dr. Anmol Bhatia
- Dr. K. Devasenathipathy
- Dr. Priyanka Narajne
- Dr. Nihaal Reddy
- Dr. Arpita Sahu
- Dr. Akshay Baheti
- Dr. Anitha Jasper
- Dr. Nikshita Jain
- Dr. Gaurav Raj
- Dr. Deeksha Bhalla

*Congratulations*



# Indian Society of Paediatric Radiology

Year: 16 Issue: 2  
Continuous issue no. : 27

(Founded in 2003)  
[www.ispronline.in](http://www.ispronline.in)

## Achievements & Awards

We congratulate **Dr. Subham Saini**, Fellow Pediatric Radiology, PGIMER, Chandigarh, for winning the Best Scientific Abstract award and securing the 1<sup>st</sup> Prize at the 25th Annual Scientific Meeting of the Asian and Oceanic Society for Paediatric Radiology (AOSPR) held at Doha, Qatar, October 2025. This grants him direct entry into oral paper category at the International Pediatric Radiology Conference at IPR, scheduled to be held in Boston in 2026.



*Congratulations*



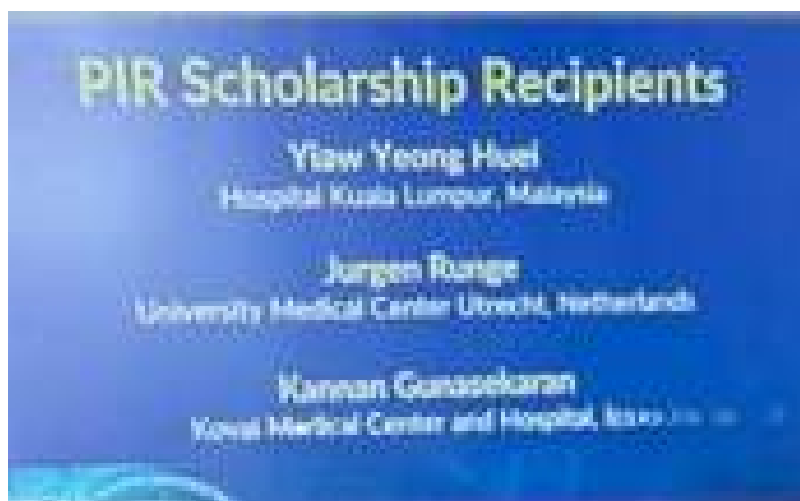
# Indian Society of Paediatric Radiology

Year: 16 Issue: 2  
Continuous issue no. : 27

(Founded in 2003)  
[www.ispronline.in](http://www.ispronline.in)

## Achievements & Awards

**Dr. Kannan Gunasekaran**, Lead Consultant, Pediatric Radiology, Kovai Medical Centre & Hospital, Tamilnadu, has been awarded the PIR Scholarship for 2025 by the Society of Pediatric Interventional Radiology (SPIR).



**Dr. Hiren Panwala**, Consultant Pediatric Radiologist & Clinical Lead, NH SRCC Children's Hospital, Mumbai, has successfully launched a Pediatric Radiology fellowship programme at his institution.

## *Congratulations*

# Indian Society of Paediatric Radiology

Year: 16 Issue: 2  
Continuous issue no. : 27

(Founded in 2003)  
[www.ispronline.in](http://www.ispronline.in)

## QUIZ ANSWER:

### CONGENITAL LOBAR EMPHYSEMA

#### Imaging findings:

##### *Frontal chest radiograph (image 1)*

Left upper lobe hyperinflation is observed with increased translucency and oligemia. Hyperinflated left upper lobe is crossing the midline. Deviation of mediastinal structures to the right. Atelectasis in right lower zone.

##### *HRCT chest :*

##### *Axial and coronal images in lung window (image 2a-2d)*

Left upper lobe reveals hypertransradiancy with hyperinflation and significant attenuation of left upper lobar vessels. Hyperinflated left upper lobe is crossing the midline across the mediastinum anteriorly. Rest of the lung parenchyma reveals compressive atelectasis with volume loss. Mediastinal structure are displaced towards right side.

**DISCUSSION:** Presentation is with breathlessness in first 6 months of life .30 % at birth and 50 % in 1st month. Respiratory distress with wheezing can be present.

M: F = 3 : 1

14 % cases are associated cardiac anomalies , renal anomalies , gastrointestinal or skin anomalies.

##### *Association :*

Left aberrant pulmonary artery.

Congenital heart defects : VSD, PDA and tetralogy of Fallot.

Masses like teratoma or foregut cyst

Bronchial atresia

Usually one lobe is affected LUL (45%), Right middle lobe ( 30 %), right upper lobe (20%), lower lobes ( 2- 10 %)

##### **Differential diagnosis:**

- Bronchial atresia
- CPAM
- Pulmonary arterial hyperplasia
- Pulmonary hypoplasia
- Swyer -James syndrome

##### **Case contributed by:**

Dr. Sneha Zanje (Jupiter Hospital, Thane)

Dr. Priya Chudgar (Jupiter Hospital, Thane)

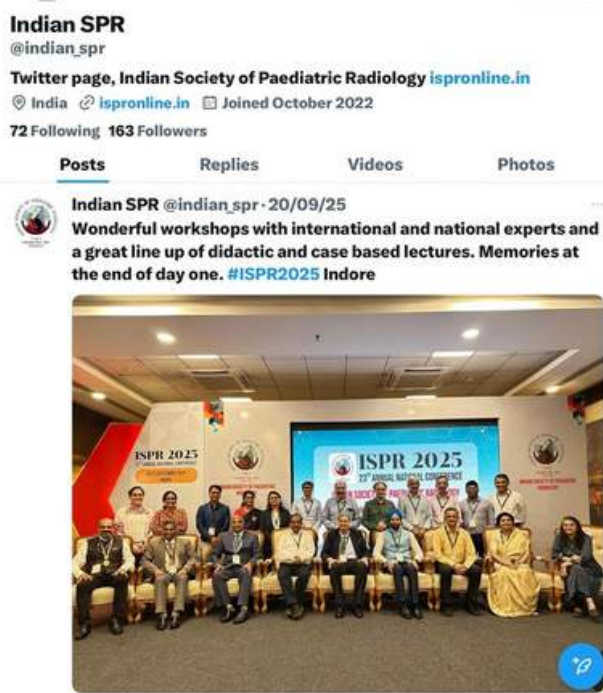

# Indian Society of Paediatric Radiology

Year: 16 Issue: 2  
Continuous issue no. : 27

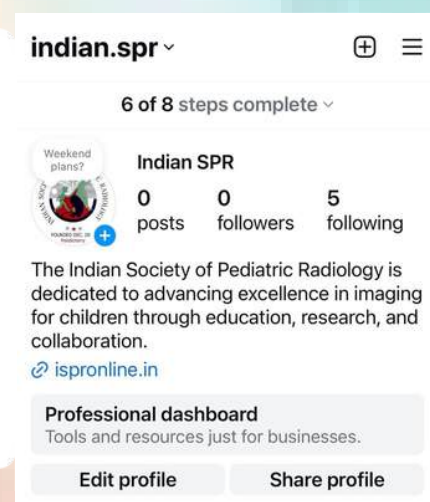(Founded in 2003)  
[www.ispronline.in](http://www.ispronline.in)

## ISPR SOCIAL MEDIA ACTIVITIES



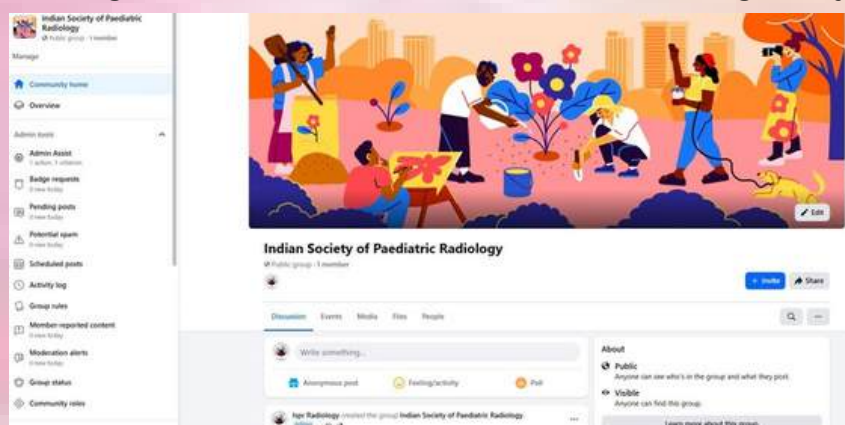
**X handle: @indian\_spr**  
managed by Dr. Taruna Yadav

**Instagram: indian\_spr**



## Facebook

Instagram and Facebook accounts managed by Dr. Ishan Kumar and Dr. Abhijeet Taori



For social media queries email: [indianspr22@gmail.com](mailto:indianspr22@gmail.com)

# Indian Society of Paediatric Radiology

Year: 16 Issue: 2  
Continuous issue no. : 27


(Founded in 2003)  
www.ispronline.in

## USEFUL RESOURCES & NORMATIVE PEDIATRIC VALUES IN DAILY PRACTICE

ULTRASOUND

<https://www.ohsu.edu/school-of-medicine/diagnostic-radiology/pediatric-radiology-normal-measurements>

Pediatric Ultrasound Multisite Conference  
[www.youtube.com/@PediatricUSMultisiteConference](http://www.youtube.com/@PediatricUSMultisiteConference)  
27 videos



The primary objective of the SPR National Pediatric Radiology Fellowship Curriculum offering is to provide fellowship programs with accessible educational material that they may use to supplement their existing lectures or fill gaps in their program's case volume and/or referral base. Additionally, it is hoped that the material will entice new trainees to choose pediatric radiology as a career and to keep our current members up to date and expertly trained.

<https://myedu.spr.org/PedRadFellowshipCurriculum>

NEURO MRI

### PITUITARY:

Singh AKC, Kandasamy D, Garg A, Jyotsna VP, Khadgawat R. Study of Pituitary Morphometry Using MRI in Indian Subjects. Indian J Endocrinol Metab. 2018 Sep-Oct;22(5):605-609. doi: 10.4103/ijem.IJEM\_199\_18. PMID: 30294567; PMCID: PMC6166545.

### CORPUS CALLOSUM:

Garel C, Cont I, Alberti C, Josserand E, Moutard ML, Ducou le Pointe H. Biometry of the corpus callosum in children: MR imaging reference data. AJNR Am J Neuroradiol. 2011 Sep;32(8):1436-43. doi:10.3174/ajnr.A2542. Epub 2011 Jul 28. PMID: 21799035; PMCID: PMC7964359.





# Indian Society of Paediatric Radiology

Year: 16 Issue: 2  
Continuous issue no. : 27

(Founded in 2003)  
[www.ispronline.in](http://www.ispronline.in)

## ISPR Office Bearers

### National President

Dr. Bijon Kundu

### Immediate PP

Dr. Akshay K Saxena

### President Elect

Dr. Kushaljit S Sodhi

### Vice Presidents

Dr. Priscilla Joshi

Dr. Jeetendra Sharma

### Secretary General

Dr. Sridhar Gibikote

### Joint Secretaries

Dr. Kushal B Gehlot

Dr. Anit Parihar

### Treasurer

Dr. Anmol Bhatia

### Executive Committee

Dr. N. Chidambaranathan

Dr. K. Gopinathan

Dr. Manisha Jana

Dr. C.V. Kanimozhi

Dr. Taruna Yadav

Dr. Hiren Panwala

Dr. Ishan Kumar



## Indian Society of Paediatric Radiology

Founded December 2003 Pondicherry

### Membership Form

#### A. Member Details

Full Name (Block Letter)

.....

Medical Registration no

.....State.....

Institution

.....

Mailing Address (Office)

.....

.....

.....Pin.....

Phone No. ....

Fax No. ....

Email ID. ....

Mobile .....



Mailing Address (Residence)

.....

.....

Pin ..... Phone No. ....

Mobile ..... Date of Birth .....

Email ID .....

Qualifications

I) .....Year.....

II) .....Year.....

III) .....Year.....

All correspondence to be addressed to : ☐ Office ☐ Residence



# Indian Society of Paediatric Radiology

Year: 16 Issue: 2  
Continuous issue no. : 27

(Founded in 2003)  
www.ispronline.in

## ISPR Office Bearers

### National President

Dr. Bijon Kundu

### Immediate PP

Dr. Akshay K Saxena

### President Elect

Dr. Kushaljit S Sodhi

### Vice Presidents

Dr. Priscilla Joshi

Dr. Jeetendra Sharma

### Secretary General

Dr. Sridhar Gibikote

### Joint Secretaries

Dr. Kushal B Gehlot

Dr. Anit Parihar

### Treasurer

Dr. Anmol Bhatia

### Executive Committee

Dr. N. Chidambaranathan

Dr. K. Gopinathan

Dr. Manisha Jana

Dr. C.V. Kanimozhi

Dr. Taruna Yadav

Dr. Hiren Panwala

Dr. Ishan Kumar

### B. Method of Payment

For Membership Amount  
Online (Preferred)  
Mode of payment : Cheque/DD  
In Favour of  
Indian Society of Paediatric Radiology

Online Payments may be made to -  
INDIAN SOCIETY OF PAEDIATRIC  
RADIOLOGY Bank Of Baroda  
S/B A/C no - 05280100026047  
IFSC - BARB0MOUNTR  
(please attach payment proof along with  
the application)

:  
Cheque/DD No. & Date.....

(Name of the Bank)

(DD No. & Date)

(Place of issue)

### C. Associate Member

Name of the Member .....

Name of Speciality .....

### D. Declaration :

I have studied (Name of the course) .....

Of..... during (Academic Year) .....

I am interested in Paediatric Radiology, am eager to join the Indian Society of Paediatric Radiology.  
I will abide by the Constitution.

Place:

Date:

(Signature)

	Admission fees	Total	
As life Member	: Rs. 8000/- + 1440/- (18% GST) =	9440/-	(Radiologist)
Associate Member	: Rs. 3000/- + 540/- (18% GST) =	3540/-	Surgeon, Physician, Paediatrician & Other Imaging Specialists) (Allied Health Professionals Interested in Paediatrics)

Please send your application + Cheque/DD + MD/DNB & Registration certificate to :

Dr. Sridhar Gibikote (isprmembership@gmail.com)  
Secretary I S P R  
Department of Radiology  
CMC Hospital, Vellore 632004, India  
Website - www.ispronline.in

Treasurer

### For Office use only

Membership No ..... Receipt issued / Not issued

No. ....